

Challenges of reconstruction of complex gunshot facial trauma in a 15-year old girl victim of banditry. A case report

Ajani AO M.D.
 Ogundele AA M.D.
 Waziri AM M.D.
 Suleiman HM M.D.
 Gbadamasi KA M.D.
 Salihu MN M.D.
 Alimi MF M.D.
 Bolaji AI M.D.
 Atoyebi SA M.D.

Kano, Nigeria

Case report

Plastic Surgery



Background: Facial trauma can be from road traffic crash, assaults, suicidal attempts or gunshot injuries. Gunshot wound (GSW) to the face accounts for 6% of all GSW. It is usually extensive, complex and very challenging to manage, requiring skill, numerous surgical procedures, patience, and long term follow up. Definitive treatment can be immediate, early or delayed. The management consist of initial stabilization, definitive reconstruction and then secondary refinement.

We present 11 year old girl who sustained complex, complete avulsion injury to the lower face following gunshot from attack by bandits in northwest Nigeria.

She multiple free flap microvascular and multiple pedicled flap surgeries for reconstruction.

Excessive and drooling of saliva, which was digesting the flap and immobilization of head and neck in pedicle flap were amongst major challenges.

After 10 months of hospital admission, she he has achieved some degree of mouth closure, tolerating oral feeding, however, she has a 0.5cm diameter fistula of lower lip and cannot chew. She awaits further mandibular and soft tissue reconstructions.

Reconstruction of facial GSW is challenging, surgery should be staged and pedicle flaps requires immobilization and control of excessive secretion of saliva.

Keywords: Facial trauma, gunshot trauma, facial reconstruction, head and neck reconstruction.

Facial trauma can be from road traffic crash, assaults, suicidal attempts or gunshot injuries. Gunshot wound (GSW) to the face accounts for 6% of all GSW. It is usually extensive, complex and very challenging to manage, requiring skill, numerous surgical procedures, patience, and long term follow up^{1,2}. Definitive treatment can be immediate, early or delayed^{3,4}. The management consist of initial stabilization, definitive reconstruction and then secondary refinement⁵.

Case report

A 15 years old, Hausa, Muslim, girl from Zamfara state, referred from a suburb hospital and presented to the accident and Emergency section of National Orthopaedic Hospital Dala, (NOHD)Nigeria, with gunshot injury to the face, eleven hours prior to presentation.

She had gunshot to her lower face when some armed bandits raided their home. She sustained complex, complete, avulsion injury of upper and lower lips, and the mandible, with exposed oedematous tongue.

The Maxillofacial Unit (MFU) resuscitated her, transfused her with 2 pints of blood, passed tracheostomy tube, did initial wound debridement and she was managed in the Intensive Care Unit. She was discharged home after six weeks of resuscitation and initial care.

She was readmitted for reconstructive surgeries five months after injury. The microvascular surgery (MVS) team was invited. Definitive surgery was, first, attempted using a vascularized fibula graft and mandibular reconstruction plate for mandibular reconstruction and rectus femoris flap for soft tissue reconstruction. Excessive salivation and drooling saliva was a challenge. The free flap became

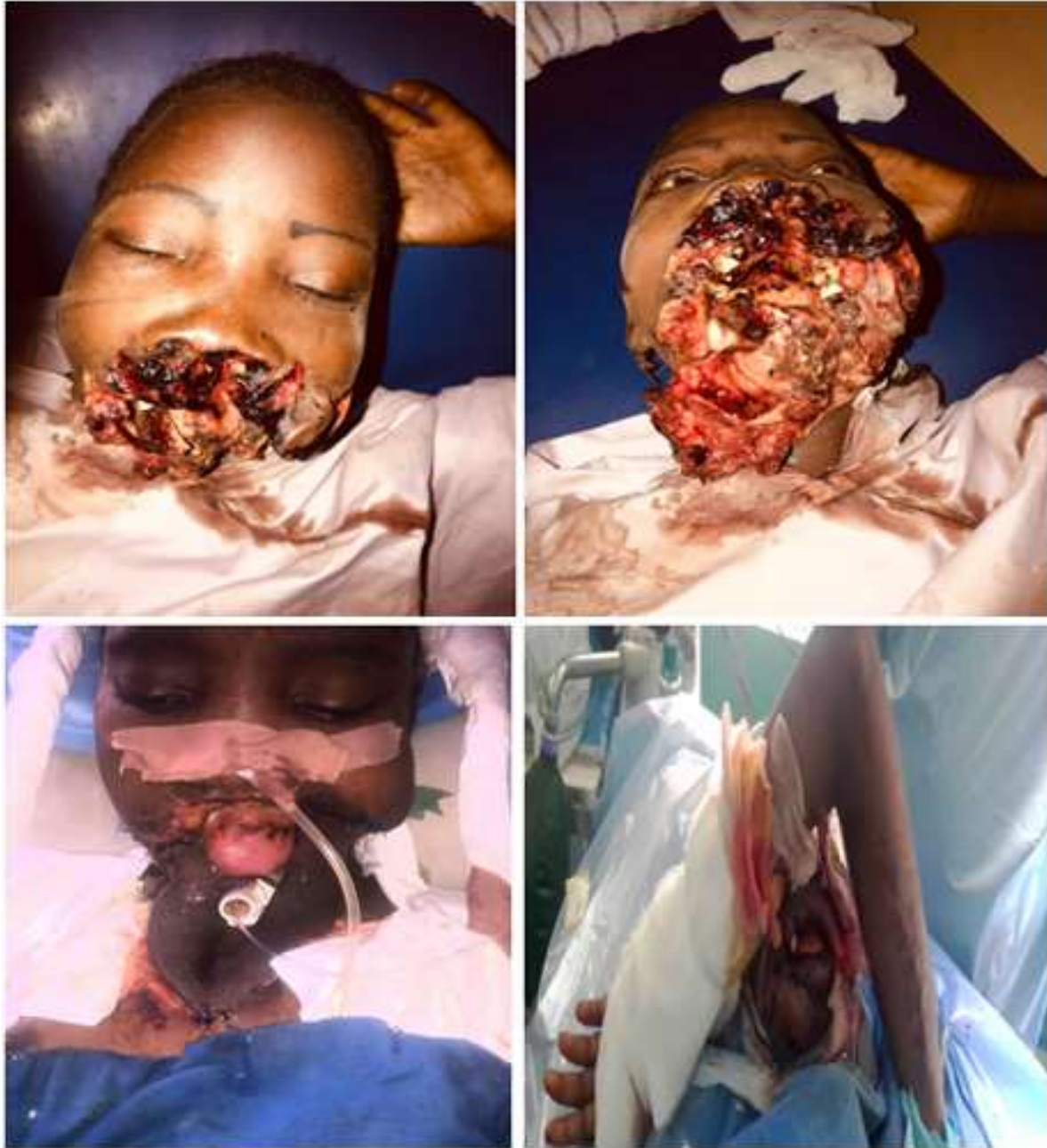


Figure 1. A,B. Clinical photographs at presentation. C. Bilateral deltopectoral flaps. D. Left radial forearm flap.

macerated and necrosed on POD 3. She was reexplored same day.

The necrosed free flap, fibula graft and construct were debrided and, in the same sitting,

bilateral deltopectoral pedicled flaps was done. The left was extended and used to reconstruct the upper lip while the right was used for the lower lip. A neck flexion splint was applied and the patient was placed on Glyco-P injection.

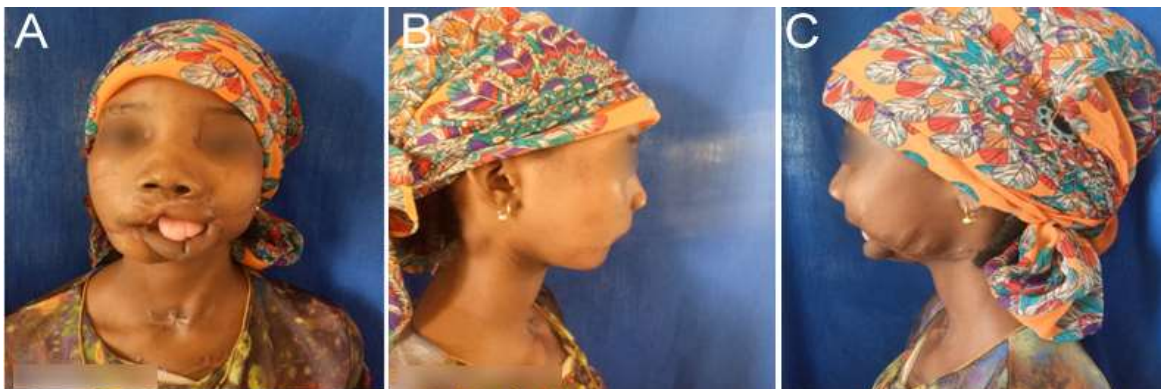

Figure 2. 5 months post-op pictures.

The left pedicle flap failed after one week and a left radial forearm flap was done and splinted.

Tracheostomy tube was removed and the patient is breathing spontaneously and saturating well at room air. She has achieved some degree of mouth closure, tolerating oral feeding, however she is still drooling saliva. She has a 0.5cm diameter fistula of lower lip. She awaits further mandibular and soft tissue reconstructions.

Conclusion

Facial GSW is very devastating usually resulting in complex injuries that requires multistaged and multispeciality reconstruction, with challenges that can complicated the outcome. Both pedicled and free flaps can be used with acceptable outcomes.

Conflicts of interests

There are no conflicts of interest

References

1. Clerk N, Birely B, Manson P, et al. High-Energy Ballistic and Avulsion Facial Injuries: Classification, Patterns, and Algorithm for Primary Reconstruction. *Plast Reconstr Surg.* 1996;4:583-601.
2. Yoav Kaufman, Patrick Cole, Larry Hollier Jr. Facial Gunshot Wounds: Trends in Management. *Craniofacial Trauma Reconstr.* 2009 May;2(2): 85-90
3. Williams CN. Immediate and Long-term Management of Gunshot Wounds to the Lower Face. *Plast Reconstr Surg.* 1988;82:433-439
4. Doctor VS, Farewell DG. Gunshot Wounds to the Head and Neck. *Curr Opin Otolaryngol Head Neck Surg.* 2007;15(4):213-218.
5. Mehrnoush MR, Farnoosh R. Maxillofacial Gunshot Injuries and their Therapeutic Challenges: Case Series. *Clin Case Reports.* 2020;8(6):1094-1100

Ajani Abdulwahab
Consultant, Microvascular and Plastic Surgeon
Burns, Plastic & Reconstructive Surgery Department,
National Orthopaedic Hospital, Kano, Nigeria.